

Quimica

Green coffee oil cream (*Coffea arabica* L.): healing potential of skin wounds of wistar rats

Creme de óleo de café verde (*Coffea arabica* L.): potencial cicatrizante de feridas cutâneas de ratos Wistar

Hudson de Almeida¹, Aline Barbosa Scarabelli¹, Rafael Fregnan Silvério¹, Miller Pereira Palhão¹, Júlia Azevedo de Almeida¹, Renato Silveira Vilas Boas Filho¹, Nelma de Mello Silva Oliveira¹, Evelise Aline Soares^{II}, Bethânia Elias Costa¹, Maria das Graças de Souza Carvalho¹, Ciderléia Castro de Lima¹, Cloves Gomes de Carvalho Filho^{III}, José Antonio Dias Garcia^{I, III}

¹Universidade José do Rosário Vellano, Alfenas, Minas Gerais, Brasil.

^{II} Universidade Federal de Alfenas, Alfenas, Minas Gerais, Brasil.

^{III} Instituto Federal de Educação, Ciência e Tecnologia do Sul de Minas Gerais, Machado, Minas Gerais, Brasil.

ABSTRACT

Objective: To evaluate the effect of 10% cream of green coffee oil on skin Wounds in Wistar Rats. **Materials and Methods:** We used 36 Wistar Rats, randomly divided between 3 groups: Inert Group (I, n = 12), Wounds were cleaned and treated with cream without the active ingredient once a day; Green Coffee (CV, n = 12), Wounds were cleaned and treated with 10% green coffee cream once a day; Dexpanthenol (SD, n = 12), Wounds were cleaned and treated with 5% Dexpanthenol once a day. As lesions had been generated by 8mm drilling, the same have been treated topically every day. On the 3rd, 7th and 14th day after Surgery, four Animals / group were sacrificed, or a Fragment of skin around the Wound was collected and processed histologically. **Results:** Green coffee cream is a 10% stimulus in the Repair process, such as Wounds without signs of infection, and an increase in the number of mononuclear Cells and fibroblasts (p 0.05), good entanglement of collagen Fibers and less healing time presented to the other studied groups. **Conclusion:** 10% green coffee oil has Pharmacological potential in the healing of skin Wounds.

Keywords: Angiogenesis; Collagen; Inflammation; Cell Proliferation; Fibroblasts

RESUMO

Objetivo: Avaliar o efeito do creme de óleo de café verde a 10% em Feridas cutâneas em Ratos Wistar. **Materiais e Métodos:** Foram utilizados 36 Ratos Wistar, divididos aleatoriamente em 3 grupos: Grupo Inerte (I, n = 12), as feridas foram limpas e tratadas com creme sem o ingrediente ativo uma vez ao dia; Café Verde (CV, n = 12), As feridas foram limpas e tratadas com creme de café verde a 10% uma vez ao dia; Dexpantenol (SD, n = 12), As feridas foram limpas e tratadas com Dexpantenol 5% uma vez ao dia. Como as lesões foram geradas pela perfuração de 8mm, as mesmas foram tratadas topicamente todos os dias. No 3^o, 7^o e 14^o dia

após a cirurgia, quatro Animais / grupo foram sacrificados, ou um Fragmento de pele ao redor da Ferida foi coletado e processado histologicamente. Resultados: O creme de café verde é um estímulo de 10% no processo de Reparação, como Feridas sem sinais de infecção, aumento do número de Células mononucleares e fibroblastos (p 0,05), bom emaranhamento das Fibras de colágeno e menor tempo de cicatrização apresentado. os outros grupos estudados. Conclusão: o óleo de café verde a 10% possui potencial farmacológico na cicatrização de feridas cutâneas.

Palavras-chave: Angiogênese; Colágeno; Inflamação; Proliferação Celular; Fibroblastos

1 INTRODUCTION

A small wound can turn into a chronic wound if not treated correctly. Chronic wounds are considered a public health problem in Brazil (BRASIL, 2002). The Ministry of Health estimates that approximately five million Brazilians suffer from chronic wounds (BRASIL, 2016). According to the National Institute of Social Security (INSS) the wounds are 10^o the largest cause of work absence in Brazil, with more than 200 thousand workers temporarily or permanently discharged (BRASIL, 2020).

Wound healing is a dynamic, complex process that involves several stages and culminates in the repair of a tissue lesion. In view of the fact that, due to the inability of tissue restoration, lost along the evolutionary scale, and in the attempt to repair the tissue and isolate the internal environment from the external, the organism reacts through a series of synchronized and integrated events. The various phases were infused, and the divisions were expected only for didactic purposes, such as the inflammatory, proliferative, and remodeling phases (MANDELBAUM; DI SANTOS; MANDELBAUM, 2003).

The acquaintance and understanding of the healing process, as well as the importance and bandage elaboration, have grown and changed expressively in the last three decades. Since, the existence of various types of wounds, those progresses differently, leading to the necessity to diversify the types of bandages. Some factors are known to interfere with the healing process, either by acting as enzyme cofactors, interfering with cellular metabolism, or altering the wound microenvironment (MÉLEGA, 2002).

Several products and therapies are being used and developed to optimize the repair of skin lesions and meet the clinical demand (BEHEREGARAY *et al.*, 2018). This is mainly

due to the ineffectiveness of some products on the market and the abusive price placed by pharmaceutical industries, in addition to the growing interest in the use of herbal medicines (COELHO *et al.*, 2010). Rahal *et al.* (2005) and Barbosa *et al.* (2009) reported that there is a variety of herbal and natural products with active ingredients that could be used to treat skin wounds, However, they have not yet been studied.

Green coffee oil (*Coffea Arábica* L.) has been widely used in the pharmaceutical and cosmetic industries to produce skin harmful emollients, moisturizers and sunscreens (LAGO, 2001; SILVA *et al.*, 2015). In its composition more than 10% is unsaponifiable material, as sterols, tocopherols and diterpenes cauranes: cafestol and caveol, are responsible for the synthesis of dermal fibers, improves the physiological balance of cells, hydration and regeneration of the skin, in addition to stimulating collagen synthesis, anti-inflammatory activity and antioxidant potential (TSUKUI; OIGMAN; REZENDE, 2014). The authors also reported that green coffee oil is one of the most effective antioxidants in the world, being able to combat aging, soften skin texture, reduce damage caused by free radicals, stimulate the synthesis of dermal fibers through its firming and regenerative effect, and also assist in the formation of ceramides and wound healing.

Considering the interest expansion in the use of herbal medicines, our research aimed to analyze the effect of cream at 10% of green coffee oil (*Coffea Arábica* L.) on skin wounds in Wistar rats (*Rattus norvegicus*) aiming at the possibility of offering a new product in the market of bandages industries.

2 MATERIAL AND METHODS

The experiment was conducted at the Research Laboratory of the Universidade José do Rosário Vellano (UNIFENAS) in Alfenas. 36 Rats have been used (*Rattus norvegicus*), Wistar, white, male, weighing 270 30g, 90 days old, obtained from the UNIFENAS Central Animal House, Campus Alfenas. The experimental protocol was approved by the Research Ethics Committee (CEP) of Universidade José do Rosário Vellano, UNIFENAS - Alfenas, registration N° 29A/2019.

2.1 OBTAINING GREEN COFFEE OIL

The green coffee oil (*Coffea Arábica* L.) was provided by the Cooperativa Regional de Cafeicultores in Guaxupé Ltda (Cooxupé), Guaxupé, Minas Gerais, Brazil. It was obtained by the method of extraction by continuous cold pressing with green coffee beans, and packed with injection of nitrogen in PET and polypropylene packaging (COOXUPÉ, 2021).

2.2 MANIPULATION OF THE CREAM

The cream had been compounded at the Compounded Pharmacy of the University José do Rosario Vellano (UNIFENAS), in which 6ml of green coffee bean oil had been mixed at 60g of the cream base, and maintained at 22°C room temperature.

2.3 EXPERIMENTAL PROTOCOL

The animals were submitted to anesthesia with Tiopentax, sodium thiopental, Cristália, Brazil (10 mg/kg) intraperitoneal (PI) and manual depilation in the dorso-cervical region, the formation of the wounds were through a circular incision of the skin through punch of 8mm. After incision the animals received subcutaneously (SC), a single dose of Dipirona (10mg/kg). The animals were randomly divided into three experimental groups, and topical wound treatments were performed after aseptic procedures using water and neutral daily detergent for 14 days: Inert Group (I, n=12), sanitized wounds and treated with cream without active ingredient once a day; Café Verde (CV, n=12), sanitized wounds and treated with green coffee oil cream at 10% once a day; Dexpanthenol (DP, n=12), sanitized wounds and treated with 5% Dexpanthenol once a day. The rats had been kept in polyethylene boxes, separately, to avoid trauma by other animals, because the wounds did not receive bandages. In addition, the solutions of the previous day's treatment were removed with daily sanitation. All animals received commercial feed (Nuvital, Brazil) and purified water "ad libitum". At the 3rd, 7th and 14th days of treatment, four animals were

euthanized from each group with lethal dose of sodium thiopental (100 mg/kg) intraperitoneal (PI).

After euthanasia, tissue samples from the healing process were collected, covering a 4mm margin of safety. The material collected on the 3rd, 7th and 14th day was fixed in formalin at 10% for 48h and included in paraffin for histological sections of 5 µm (JUNQUEIRA; CARNEIRO 2004). For general morphological analysis and counting of mononuclear cells, neovessels and fibroblasts the slides received hematoxylin-eosin staining (HE), and for visualization of the density of the collagen fibers, the slides were stained with Picrosíriusred. The histological sections in HE and Picrosíriusred were scanned by the PANORAMIC DESK scanner of 3D HISTECH with an increase of 400x and later analyzed through the Pannoramicviewer program.

2.4 STATISTICAL ANALYSIS

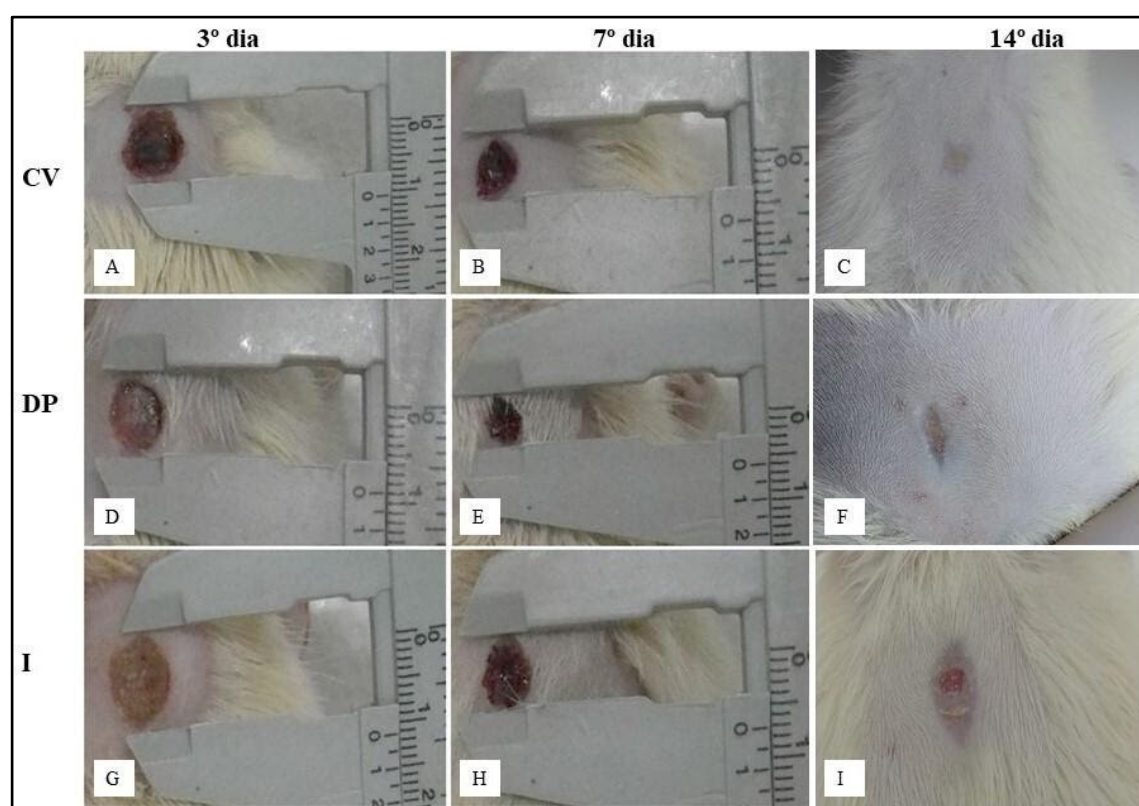
Eight fields of each histological cut per animal underwent analyses in which the mean number of mononuclear cells, neovessels and fibroblasts were calculated. The result of this count was statistically evaluated by the ANOVA and compared by the Tukey test, with significance $P > 0.05$ and the results were expressed by the mean standard error of the mean (mean EPM).

3 RESULTS

During the experiment, the animals gained weight and there were no significant differences between the groups. As for the consumption of a liquid and solid diet, there was no significant difference between the groups, and it was sufficient to provide hydration and energy necessary to maintain daily body activities. In the clinical evaluation of cutaneous wounds (Figure 1), the animals in the 10% green coffee oil cream group (CV), presented moderate accumulation of crusts on the lesion and obtained complete healing on the 13th day of treatment, with good aesthetic appearance. The Dexpanthenol group (PD) was characterized by a good initial evolution, with visible contraction of the wound

edges until the seventh day of treatment, but did not demonstrate complete healing at the end of the experiment. The cutaneous wounds of the inert group (I) did not promote accumulation of crusts, and did not demonstrate good contraction of the edges, besides that, at the 14th day of treatment the wounds were not completely healed.

Figure 1 - Image demonstrating the clinical evolution of the cutaneous wounds of rats (*Rattus norvegicus*), on the 3rd, 7th and 14th day of testing of the green coffee (CV) groups (A-C), dexpanthenol (DP) (D-F) and inert (I) (G-I)



Fonte: autores, 2019

In the analysis of histological sections of cutaneous wounds of rats, the behavior of tissue mononuclear cells present in wounds differed ($p > 0.05$) between treatments (Table 1). The initial increase in the number of mononuclear cells occurred earlier in wounds treated with Dexpanthenol and green coffee cream when compared to the inert group (Table 1 and figure 2). Subsequently, between days 7 and 14, while in DP and CV groups the number of tissue mononuclear decreases significantly, in-group I there is an increase in the number of these cells.

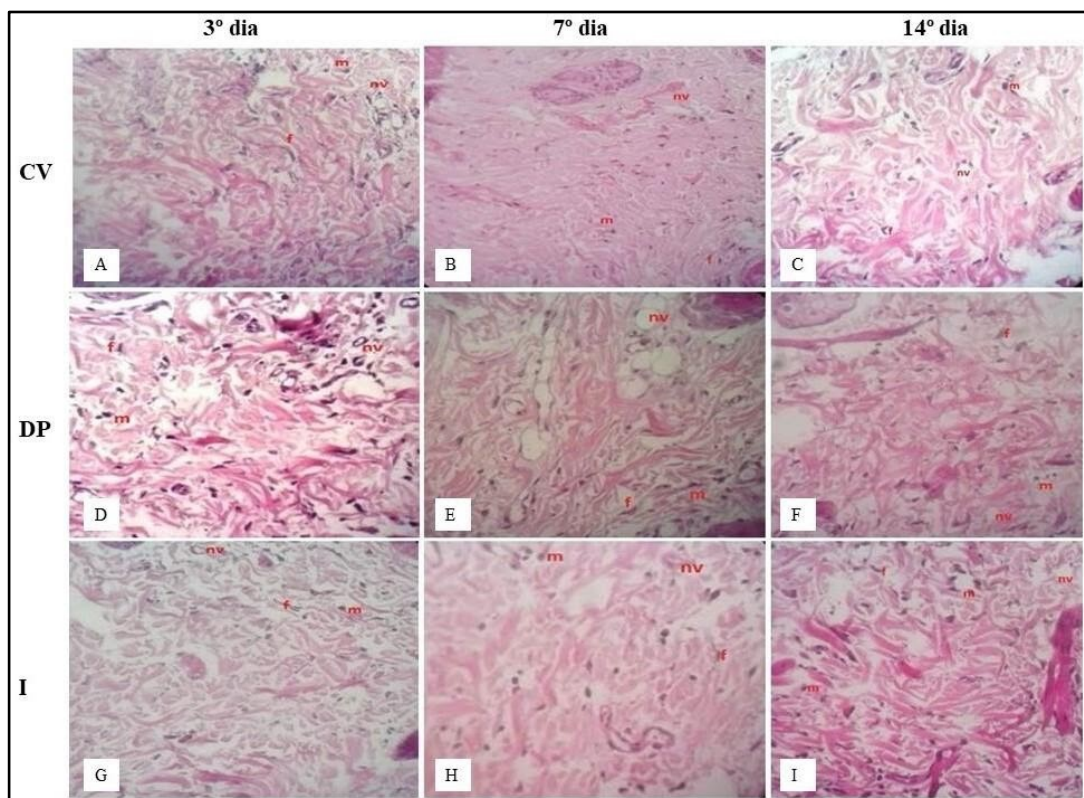
Table 1 – Mean number of fibroblasts, mononuclear cells and neovases per field of histological sections of cutaneous wounds of Wistar rats (*Rattus norvegicus*), day 3 (A-C), day 7 (D-F), and day 14 (G-I) of inert groups (I), green coffee (CV) and dexpanthenol (DP).

		I	DP	CV
3ºday	Fibroblasts / field	7,4±1,5 ^{a,b}	4,5±0,9 ^c	5,2±0,9 ^b
	Mononuclear cells / field	38,6±6 ^b	41,6±5 ^a	52,0±6 ^a
	Neovases /field	4,2±0,4 ^a	4,0±0,5 ^a	4,0±0,3 ^a
7ºday	Fibroblasts / field	3,8±0,6 ^b	10,4±1,3 ^b	27,0±3,8 ^a
	Mononuclear cells / field	42,6±4,2 ^b	70,5±6 ^a	95,5±8 ^a
	Neovases /field	2,1±0,8 ^{a,b}	2,9±0,4 ^a	1,6±0,3 ^b
14º day	Fibroblasts / field	10,4±1,7 ^b	37,9±3,2 ^a	37,5±4,5 ^a
	Mononuclear cells / field	88,6±9,3 ^a	32,8±3 ^b	41,5±3,9 ^b
	Neovases /field	1,7±0,5 ^b	2,4±0,4 ^b	1,0±0,2 ^a

Fonte: autores, 2019

The results were exposed in the Standard Error of the mean (X EPM). Two means followed by the same letter are not different from each other ($p>0.05$) at Tukey's test.

Figure 2- Photomicrographs of histological sections of cutaneous wounds of rats (*Rattus norvegicus*), stained with Hematoxylin-Eosin (HE), day 3, 7 and 14 in the green coffee (CV) groups (A-C) Dexpanthenol group (DP) (D-F) and inert (I) (G-I)



Fonte: autores, 2019

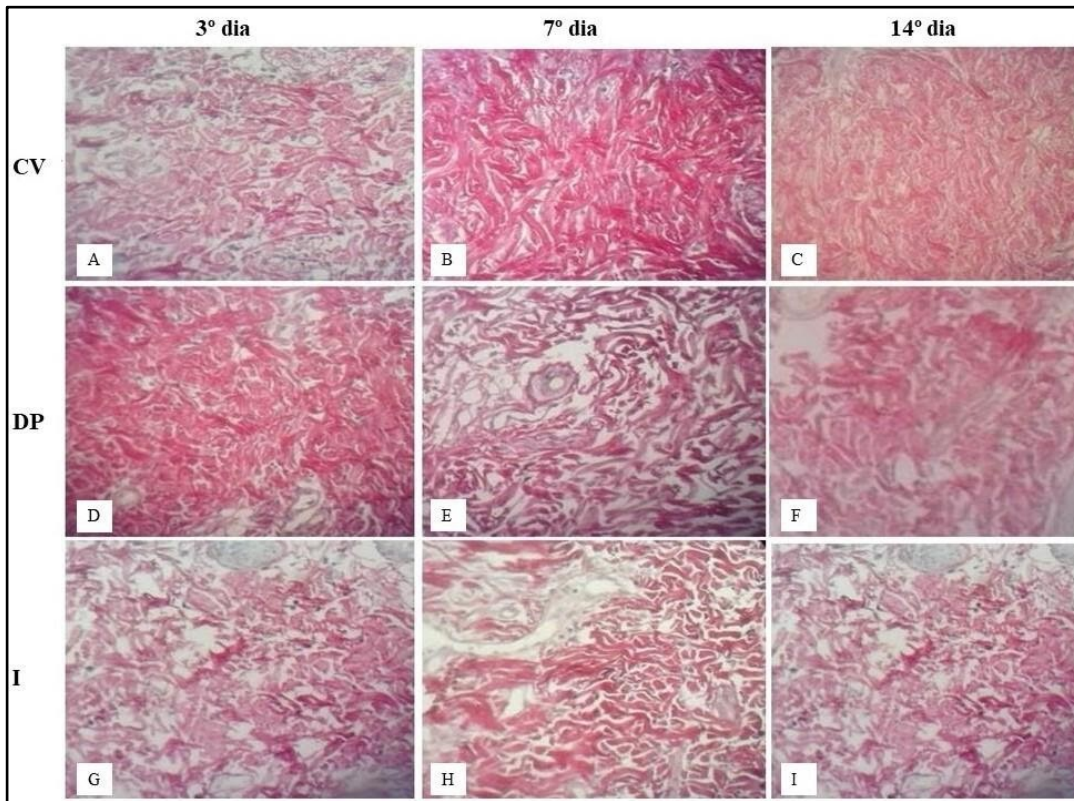
Demonstrating mononuclear cells (m), neovessels (nv) and fibroblasts (f).

The number of neovessels did not differ ($p>0.05$) between treatments on the 3rd day (Table 1). However, there was a marked decrease in this parameter between the 3rd and 7th days in all evaluated groups. The animals treated with 10% green coffee oil decreased more sharply, leading to a decrease in the numbers of neovases in the CV group when compared to the SD and I groups (Figure 2), which did not present differences between themselves at the end of the experiment.

Regarding the fibroblasts present in the cutaneous wound, the analyses indicate that the treatment of the CV group promoted a marked increase between the 3rd and 7th day, and remained at the 14th. In the treatment with Dexpanthenol, this gradual elevation had also been observed throughout the experiment, and did not differ from the CV group at the 14th day. Contrarily, group I showed a lower number of fibroblasts on day 7 with a significant increase 14th day, but with lower expression in relation to the other groups studied (Table 1 and figure 2).

The composition of collagen presented difference in relation to the thickness of the fibers and their interlacing between the groups during the analysis of the experiment. On the 3rd day, the PD group presented collagen fibers with greater interlacing and thickening in relation to the other two groups. However, on the 7th and 14th days, there was a greater distribution and interlacing of collagen fibers in the CV group, which presented thinner fibers as well as organized in the 14th days in relation to the SD and I groups (Figure 3).

Figure 3 - Photomicrography of histological sections of cutaneous wounds stained with Red Picrosyrian (PR), demonstrating the organization of collagen fibers on the 3rd, 7th and 14th day in the green coffee (J-M), Dexpanthenol P (N-P) and inert (Q-S) groups. (400x)



Fonte: autores, 2019

4 DISCUSSION

In the present study, the animals in the group treated with 10% green coffee oil cream (CV) presented shorter healing time and better appearance of the lesion in relation to the other experimental groups. In addition, wounds with viable tissue with no signs of apparent infection and excessive exudate formation with complete closure on the 13th day of the experiment were observed.

The first stage of healing (inflammatory phase) is characterized by the predominance of phagocytic cells such as neutrophils and macrophages, and are essential in the repair process because they phagocytize pathogenic microorganisms and secrete cytokines, lymphocytes and growth factors: platelet derivative (PDGF), tumor alpha (TGF- α), tumor beta (TGF- β), fibroblasts (FGF) and endothelial vascular (VEGF), which act as molecular

signaling devices and provide healing evolution (STEENKAMP *et al.*, 2004; PARK; BARBUL, 2004; MEDEIROS; DANTAS-FILHO, 2016).

We noted in our study, that the mononuclear cells of the CV and SD group remained accentuated at the beginning of the cicatricle process and were gradually decreasing. However, the wounds of the CV group presented complete closure of the lesion at the end of the experiment, unlike the SD group. This result is due to the considerable presence of linoleic acid (CARMO, 2019), caffestol and caveol (CHARTIER *et al.*, 2013), present in green coffee oil. These compounds have antioxidant effects, in addition to interfering in the inflammatory cascade as they decrease the formation and mediators of inflammation mainly by inhibiting the enzyme such as phospholipase A2, lipoxygenases and cyclooxygenases, reducing the formation of prostanoids and leukotrienes (COSTA *et al.*, 2012; DEEPA; RENUKA, 2014).

A study by Cárdenas *et al.*, (2011), demonstrated that in addition to the anti-inflammatory effect, caveol also presented antiangiogenic effects. This event was observed in our study, in which the number of new vessels not on the 7th and 14th day of the CV group fell more significantly than the other groups studied.

With the inflammatory process installed and the release of the chemical mediators of inflammation, there was a attract neutrophils and macrophages to the wound and take part in all the clinical manifestations of the inflammatory process. These cells play an important role against bacterial contamination by means of phagocytosis, and production and release of proteinases and reactive oxygen species (ROS). In addition to inflammatory cells, other cell types, such as fibroblasts, can also produce ROS in response to pro-inflammatory cytokines (MEIER *et al.*, 1989). The local ROS increase is important for the defense against microbial infection; however, the prolonged production of high levels of ROS can induce cell damages (CERUTTI; TRUMP, 1991). ROS can also activate and maintain the inflammatory aradonic acid cascade (TRENAM *et al.*, 1991).

In our study, we observed that on the 7th day of the experiment, mononuclear cells and fibroblasts from the CV group were in evidence, demonstrating a direct relationship. However, the increase in the number of fibroblasts remained high in the CV group on the

14th day, similar to the DP group; contrary to the result of mononuclear cells, there was a decrease, compared to group I. This behavior is expected by these cells in the healing process in the maturation phase, in which there is a decrease in mononuclear cells and an increase in fibroblasts.

The significant presence of fibroblasts at the beginning of the CV group repair process contributed to the consolidation of the wound at the end of the 13th day, in addition to provide greater interlacing and reorganization of the collagen fibers, giving the tissue greater rigidity and resistance. This result is attributed to the composition of green coffee oil rich in fatty acids, which stimulates the production of collagen and the proliferation of fibroblasts (VOYTENA, 2017).

5 CONCLUSION

Based on the experimental model proposed in this study, we concluded that the coffee oil cream at 10% presented potential in the healing process in a shorter time, demonstrating chemotactic capacity for mononuclear cells, anti-inflammatory and extracellular matrix stimulator, such as collagen, which is a promising product in the dressing industry market.

ACKNOWLEDGMENT

UNIFENAS, CAPES for the financial support and grant, and the Cooperativa Regional de Cafeicultores in Guaxupé Ltda (Cooxupé), Guaxupé, Minas Gerais, Brazil, for supplying green coffee oil.

REFERENCES

- BARBOSA, Maria Helena *et al.* Ação terapêutica da própolis em lesões cutâneas. **Acta paul. enferm.**, São Paulo, v. 22, n. 3, p. 318-322, Jun. 2009.
- BEHEREGARAY, Wanessa Kruguer *et al.* Tratamento de ferida por eletroacupuntura em uma gata. **Acta Scien Vet.**, Porto Alegre, v. 37, n. 3, p. 289-295, Mar. 2018.

BRASIL. Ministério da Economia. Dados estatísticos. **Previdência Social e INSS**. 2020. Disponível em: <http://www.previdencia.gov.br/dados-abertos>.

BRASIL. Ministério da Saúde. Secretaria de Atenção à Saúde. **Manual do pé diabético: estratégias para o cuidado da pessoa com doença crônica**. 1. ed. Brasília: Ministério da Saúde, 2016.

BRASIL. Ministério da Saúde. Secretaria de Políticas de Saúde. **Manual de condutas para úlceras neurotróficas e traumáticas**. Cadernos de Reabilitação em Hanseníase; 1. ed. n. 2. Brasília: Ministério da Saúde, 2002.

CÁRDENAS, Casimiro; QUESADA, Ana; MEDINA, Miguel. Anti-Angiogenic and Anti-Inflammatory Properties of Kahweol, a Coffee Diterpene. **PLoS One**, v. 6, n. 8, p. e23407, Aug. 2011.

CARMO, Lorrany Ramos. **Caracterização do óleo de café verde e a solubilidade**. Monografia (Bacharel em Engenharia dos alimentos) – Universidade Federal de Lavras, Lavras, 2019.

CERUTTI, P.; TRUMP, B. F. Inflammation and Oxidative Stress in Carcinogenesis. **Cancer Cell**, v. 3, n. 5, p. 1-7, jan. 1991.

CHARTIER, Agnes *et al.* Optimization of the isolation and quantitation of kahweol and cafestol in green coffee oil. **Talanta**, v. 15, n. 117, p. 102-111, dez. 2013.

COELHO, Julice Medeiros *et al.* O efeito da sulfadiazina de prata, extrato de ipê-roxo e extrato de barbatimão na cicatrização de feridas cutâneas em ratos. **Rev. Col. Bras. Cir.**, Rio de Janeiro, v. 37, n. 1, p. 045-051, fev. 2010.

COOXUPÉ – Cooperativa Regional de Cafeicultores em Guaxupé LTDA. **Óleo de café**. 2021. Disponível em: <https://www.cooxupe.com.br/oleodecafe/#page/2>

COSTA, Gabrielle *et al.* Intracellular signaling pathways modulated by phenolic compounds: application for new anti-inflammatory drugs discovery. **Current Medicinal Chemistry**, v. 19, n. 18, p. 2876-2900, 2012.

DEPPA, Murugesan; RENUKA, Deviponnuswamy. Potential anti-inflammatory medicinal plants. **International Journal of Pharmacy and Pharmaceutical Sciences**, v. 6, n. 4, p. 43-49, 2014.

JUNQUEIRA, Luiz Carlos Uchôa.; CARNEIRO, José. **Histologia Básica: texto e atlas**. 10. ed. Rio de Janeiro: Guanabara Koogan, 2004.

LAGO, Regina. Lipídeos em Grãos de Café. **Bol. Centro Pesq. Process. Aliment.**, Curitiba, v. 19, n. 2, p. 319-340, jul-dez. 2001.

MANDELBAUM, Samuel Henrique.; DI SANTIS, Érico pompado.; MANDELBAUM, Maria Helena Sant'ana. Cicatrização: conceitos atuais e recursos auxiliares - Parte I. **An. Bras. Dermatol.**, Rio de Janeiro, v.78, n. 4, p. 393-408, jul-ago. 2003.

MEDEIROS, Aldo Cunha.; DANTAS-FILHO, Antônio Medeiros. Cicatrização das feridas cirúrgicas. **J. Surg. Clin. Res.**, Natal, v. 7, n. 2, p. 87-102, Mar. 2016.

MEIER, Brian *et al.* Human fibroblasts release reactive oxygen species in response to interleukin-1 or tumour necrosis factor- α . **Biochemical Journal**, v. 263, n. 2, p. 539-545, out. 1989.

MÉLEGA, José Marcos. **Cirurgia Plástica Fundamentos e Arte: Princípios Gerais**. 1. ed. Rio de Janeiro: MEDSI, 2002.

PARK, Julie.; BARBUL, Adrian. Understanding the role of immune regulation in wound healing. **Am J Surg.**, Birmingham, v. 187, n. 5, p. 11-16, mai. 2004.

RAHAL, Scheila *et al.* Utilização de própolis ou mel no tratamento de feridas limpas induzidas em ratos. **Arch Vet Sci.**, Curitiba, v. 8, n. 1, p. 61-67, abr. 2005.

SILVA, Luciano Luiz *et al.* Parametrização das condições de obtenção do extrato do café verde e torrado com co2 supercrítico. **Coffe Science.**, Lavras, v.10, n. 1, p. 65-75, mar-ago. 2015.

STEENKAMP, Vanessa *et al.* Studies on antibacterial, antioxidant and fibroblast growth stimulation of wound healing remedies from South Africa. **J. Ethnopharmacol.**, v. 94, p. 353-357, dez. 2004.

TRENAM, CW *et al.* The role of iron in an acute model of skin inflammation induced by reactive oxygen species. **British Journal of Dermatology**, v. 126, n. 3, p. 250-256, 1992.

TSUKUI, Anna.; OIGMAN, Silvia.; REZENDE, Cláudia. Óleo de Grãos de Café Cru: Diterpenos Cafestol e Caveol. **Rev Virt Quím.**, v. 6, n. 1, p. 16-33, jan-fev. 2014.

VOYTENA, Ana Paula Lorezen. **Caracterização do perfil químico e avaliação de segurança e eficácia in vitro do óleo de café (Coffea arabica L.) visando aplicação cosmética**. Tese (doutorado em Biologia Celular e do Desenvolvimento) – Universidade Federal de Santa Catarina, Florianópolis, 2017.

CONTRIBUIÇÕES DE AUTORIA

1 - Hudson de Almeida

Médico do Hospital Universitário e docente da disciplina de Bases da Técnica Cirúrgica, Universidade José do Rosário Vellano.

<https://orcid.org/0000-0001-6802-1738> - driudson@hotmail.com

Contributions: Conceptualization, data curation, formal analysis, investigation, methodology, validation, visualization, writing – original draft, writing – review & editing

2 - Aline Barbosa Scarabelli

Médica Residente de Infectologia no Hospital Heliópolis, Universidade José do Rosário Vellano.

<https://orcid.org/0000-0001-7391-4354> - alinescarabelli@hotmail.com

Contributions: Data curation, formal analysis, investigation, validation, visualization writing – original draft, writing – review & editing

3 - Rafael Fregnan Silvério

Médico residente em Medicina de Emergência no Hospital Santa Marcelina, Universidade José do Rosário Vellano.

<https://orcid.org/0000-0001-5672-8779> - rafafregnan@hotmail.com

Contributions: Data curation, formal analysis, investigation, validation, visualization, writing – original draft, writing – review & editing

4 - Miller Pereira Palhão

Doutor em Zootecnia, Universidade José do Rosário Vellano.

<https://orcid.org/0000-0002-6670-4946> - miller.palhao@unifenas.br

Contributions: Conceptualization, data curation, formal analysis, methodology, project administration, software, supervision, validation, visualization, writing – original draft, writing – review & editing

5 - Júlia Azevedo de Almeida

Graduada em Medicina, Universidade José do Rosário Vellano

<https://orcid.org/0000-0001-5803-6186> - juzevedo1602@hotmail.com

Contributions: Data curation, formal analysis, investigation, validation, visualization, writing – original draft, writing – review & editing

6 - Renato Silveira Vilas Boas Filho

Graduando Medicina, Universidade José do Rosário Vellano

<https://orcid.org/0000-0001-7661-4357> - renatofilhov@hotmail.com

Contributions: Data curation, formal analysis, investigation, validation, visualization, writing – original draft, writing – review & editing

7 - Nelma de Mello Silva Oliveira

Doutora em Ciências dos Alimentos, Universidade José do Rosário Vellano

<https://orcid.org/0000-0002-1114-2018> - nelma.oliveira@unifenas.br

Contributions: Conceptualization, formal analysis, funding acquisition, investigation, methodology, project administration, resources, supervision, validation, visualization, writing – original draft, writing – review & editing

8 - Evelise Aline Soares

Doutora em Biologia Celular e Estrutural, Universidade Federal de Alfenas

<https://orcid.org/0000-0001-7838-687X> - evelise.soares@unifal-mg.edu.br

Contributions: Conceptualization, formal analysis, funding acquisition, methodology, resources, software, validation, visualization, writing – original draft, writing – review & editing

9 - Bethânia Elias Costa

Mestrado em Medicina Veterinária, Universidade José do Rosário Vellano

<https://orcid.org/400002-85149028> - bethaniaelias@hotmail.com

Contributions: Formal analysis, investigation, methodology, validation, visualization, writing – original draft, writing – review & editing

10 - Maria das Graças de Souza Carvalho

Mestranda em Reprodução, Sanidade e Bem-Estar animal, Universidade José do Rosário Vellano

<https://orcid.org/0000-0001-8726-6327> - mariah_roots@hotmail.com

Contributions: Conceptualization, formal analysis, investigation, methodology, validation, visualization, writing – original draft, writing – review & editing

11 - Ciderléia Castro de Lima

Doutoranda em Enfermagem, Universidade José do Rosário Vellano

<https://orcid.org/0000-0002-7737-3935> - ciderleiacastro@yahoo.com.br

Contributions: Conceptualization, formal analysis, funding acquisition, investigation, methodology, project administration, software, validation, visualization, writing – original draft, writing – review & editing

12 - Cloves Gomes de Carvalho Filho

Doutor em Ciências, Instituto Federal de Educação, Ciência e Tecnologia do Sul de Minas Gerais.

<https://orcid.org/0000-001-7026-4253> - cloves.filho@ifsuldeminas.edu.br

Contributions: Conceptualization, formal analysis, investigation, methodology, validation, visualization, writing – original draft, writing – review & editing

13 - José Antonio Dias Garcia

Doutor em Biologia Funcional e Molecular, Universidade José do Rosário Vellano, Instituto Federal de Educação, Ciência e Tecnologia do Sul de Minas Gerais.

<https://orcid.org/0000-0002-4024-3045> - jadiasgarcia@gmail.com

Contributions: Conceptualization, Data curation, Formal Analysis, Funding acquisition, Investigation, Methodology, Project administration, Resources, Software, Supervision, Validation, Visualization, Writing – original draft, Writing – review & editing

COMO CITAR ESTE ARTIGO

ALMEIDA, H.; SCARABELLI, A. B.; SILVÉRIO, R. F.; PALHAO, M. P.; ALMEIDA, J. A.; VILAS BOAS FILHO, R. S.; OLIVEIRA, N. M. S.; SOARES, E. A.; COSTA, B. E.; CARVALHO, M. G. S.; LIMA, C. C.; CARVALHO FILHO, C. G.; GARCIA, J. A. D. Green coffee oil cream (*Coffea arabica* L.): healing potential of skin wounds of wistar rats. *Ciência e Natura*, Santa Maria, v. 43, e59, p. 1–15, 2021. Disponível em: <https://doi.org/10.5902/2179460X63569>. Acesso em: dia, mês (abreviado), ano.